



Perioperative Airway Management:
Update on Tools and Techniques


Toni Felberg, M.D., FAAP
Assistant Professor of Anesthesiology and Pediatrics
Baylor College of Medicine
Texas Children's Hospital
Houston, Texas


 Texas Children's Hospital

 BCM

Disclosures

◆ None


 Texas Children's Hospital


 BCM

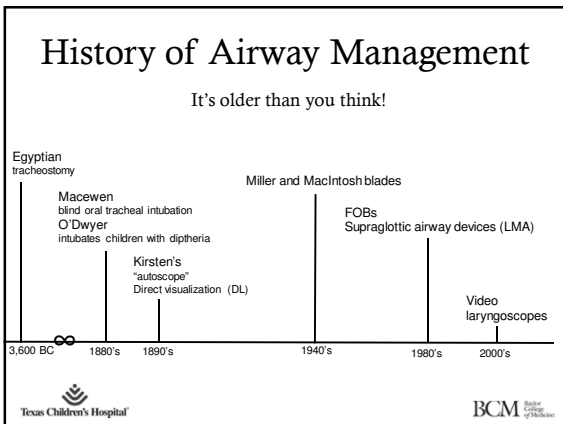
Goals

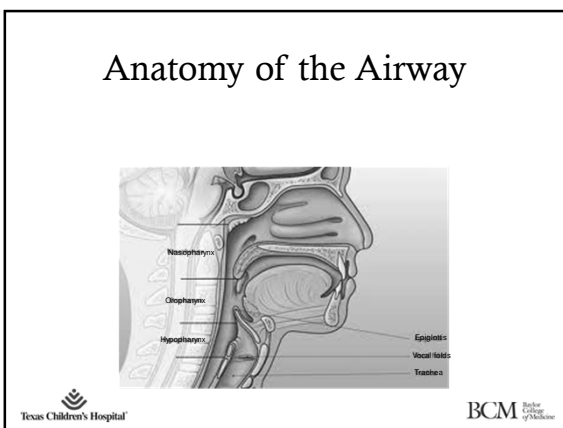
- ◆ Gain a better understanding of the range of tools and techniques utilized by the anesthesiologist for perioperative airway management.

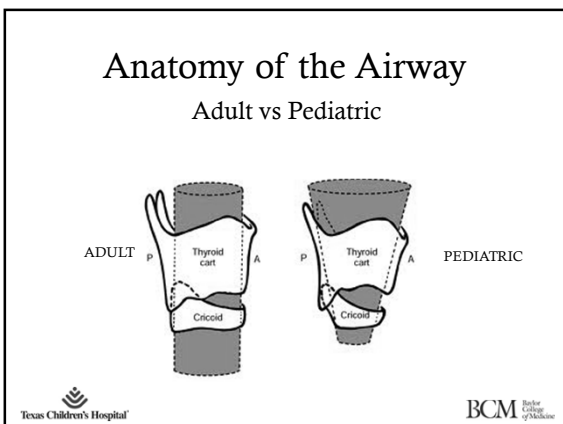
- ◆ Recognize how airway management impacts the post-operative care of the patient

 Texas Children's Hospital

 BCM








Evaluation of the Airway

- ◆ All airway classification is trying to answer 2 questions:
 - ◆ 1.) Can I mask ventilate?
 - ◆ 2.) Will I be able to intubate?



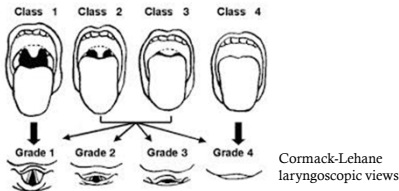
“NO” to both = difficult airway

Texas Children's Hospital BCM Baylor College of Medicine

Evaluation of the Airway

Do you see what I see ?

Modified Mallampati classification



Class 1 Class 2 Class 3 Class 4


Grade 1 Grade 2 Grade 3 Grade 4

Cormack-Lehane laryngoscopic views

Texas Children's Hospital BCM Baylor College of Medicine

Securing the Airway...

What does that mean ?

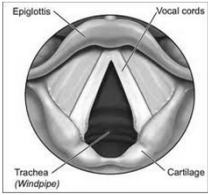


Most reliable is ETT between the vocal cords

Texas Children's Hospital BCM Baylor College of Medicine

Securing the Airway


“Grade I” view of the larynx



Texas Children's Hospital BCM Baylor College of Medicine

Securing the Airway


Why do we care ?




Because we hate to see this

Texas Children's Hospital BCM Baylor College of Medicine

Airway Tools



- ◆ Direct Laryngoscopy (DL)
- ◆ Flexible Fiberoptic Bronchoscopy
- ◆ Airway Wands
- ◆ Video Laryngoscopy
- ◆ Supraglottic Airways
- ◆ MISC: retrograde wire, blind intubation, jet ventilation, cricothyotomy





Texas Children's Hospital BCM Baylor College of Medicine

Direct Laryngoscopy

Over 80 years old

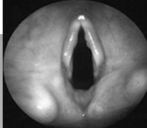


- ◆ Described late 1800's, in clinical use since 1913. Miller and MacIntosh blades developed in 1940's still used in 2012.
- ◆ Simplest, most common method of intubation.
- ◆ Indications: Placement of ETT when advanced airway support is needed. May be for surgical or medical reasons.
- ◆ Limitations: Patient position, oral opening, limited neck mobility, inability to align the airway axis's
- ◆ Nursing implications: sore throat, hoarseness, dysphagia, injury to teeth or soft tissue



Texas Children's Hospital BCM Baylor College of Medicine

Flexible Fiberoptic Bronchoscopy

FOBs



Texas Children's Hospital BCM Baylor College of Medicine

Flexible Fiberoptic Bronchoscopy


FOBs

- ◆ In medical use since 1966, it wasn't until the 1980's for intubation of the airway.
- ◆ Light source, insertion cord and handle. Visualization is at distal end of scope and transmitted via fiberoptic bundle to eyepiece. Can be performed awake or asleep, oral or nasal.
- ◆ Indications: difficult airway, limited oral opening, limited neck mobility, difficult DL but able to mask ventilate
- ◆ Limitations: copious blood and secretions, uncooperative patient
- ◆ Nursing implications: difficult airway?, assist with equipment, sore throat, hoarseness, dysphagia

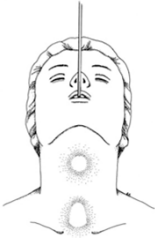
Texas Children's Hospital BCM Baylor College of Medicine



Airway wands

Traditional Light Wand




- ◆ Used as early as 1957, light at distal end of the device facilitates blind intubation technique, neck/larynx is illuminated. ETT is loaded over the stylet.
- ◆ Indications: limited oral opening, facial trauma, limited neck mobility, copious blood or secretions
- ◆ Limitations: no direct visualization of ETT placement, not used with suspected laryngeal trauma or hypoxic patient, obesity may limit transillumination.
- ◆ Nursing implications: difficult airway?, assist with equipment, trauma to airway from blind probing, hoarseness, dysphagia








Airway Wands



Optical stylet





- ◆ Indirect visualization for the operator via eye piece, introduced in 1995
- ◆ Indications: limited oral opening, limited neck mobility
- ◆ Limitations: laryngeal trauma, hypoxic patient, copious secretions, lens may fog
- ◆ Nursing implications: difficult airway?, assist with equipment, sore throat, hoarseness, dysphagia

Video Laryngoscopy

- ◆ Introduced into clinical practice in 2001 combines the tools of DL with optics transmitted to a LCD monitor.
- ◆ Permits visualization of airway by others, FOB now have this capacity
- ◆ Indications: difficult airway, limited neck mobility, difficult DL but able to mask ventilate
- ◆ Limitations: copious blood and secretions, oral opening less than 2 cm, learning curve
- ◆ Nursing implications: difficult airway?, assist with equipment, sore throat, hoarseness, dysphagia

Supraglottic Airway Devices

Does \neq secure




Texas Children's Hospital

BCM Baylor College of Medicine

Laryngeal Mask Airway

LMA

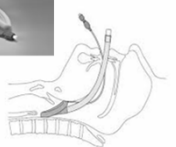



- 1983 Dr. AJ Brain introduced the most innovative advance in airway management since DL. Placement of a mask into the hypopharynx and advanced to cover the laryngeal opening.
- Indications: provide patent airway in lieu of traditional mask ventilation, routine airway in the OR, difficult intubation, airway rescue
- Limitations: severe upper airway obstruction, patient position, full stomach, PPV with high peak airways
- Nursing implications: difficult airway?, airway is not "secure", nerve injury with resultant vocal cord dysfunction

Texas Children's Hospital

BCM Baylor College of Medicine

Laryngeal Mask Airway





Texas Children's Hospital

BCM Baylor College of Medicine

Esophageal-Tracheal Combitube

Combitube




- ◆ Conceived of in 1960's, introduced into clinical practice 1980's. Blind insertion of a double lumen tube to allow airway management
- ◆ Indications: primarily used in out of hospital by providers with limited airway training, difficult airway
- ◆ Limitations: esophageal, pharyngeal or laryngeal injury, supraglottic obstruction
- ◆ Nursing implications: device recognition

Texas Children's Hospital BCM Baylor College of Medicine

Cuffed Oropharyngeal Airway

COPA



- ◆ 1990's saw the development of the COPA. Modified oral airway has a cuff at the distal end and a connector for an anesthesia circuit on the proximal end
- ◆ Indications: provide patent airway in lieu of traditional mask ventilation in SV patient
- ◆ Limitations: severe upper airway obstruction, patient position, full stomach, need for PPV
- ◆ Nursing implications: device recognition, not in common use

Texas Children's Hospital BCM Baylor College of Medicine

Additional Anesthesia Tools

Airway Monitoring



- ◆ Oxygenation Pulse Oximetry

- ◆ Ventilation Capnography

Texas Children's Hospital BCM Baylor College of Medicine

Risk Factors for Hypercapnia



- ◆ PMH
- ◆ Opioids
- ◆ Respiratory Impairment
- ◆ Positioning

Additional Anesthesia Tools


Medications

- ◆ Sedatives/Narcotics
 - ◆ Dexmetomidine
 - ◆ Remifentanyl
- ◆ Antiemetics
 - ◆ Ondansetron
 - ◆ Decadron

Emergency Treatment of Laryngospasm

- ◆ Recognition
- ◆ Airway maneuvers
- ◆ Medications

Conclusions

Implications for Perioperative Nurses

- ◆ Knowledge of the anesthesia tools used for your patient will enhance your care via anticipation of possible complications.
- ◆ Ask appropriate questions relating to the airway management used:
 - * Was this a difficult airway?
 - * What are the unique post op complications I can anticipate?
 - * Does this patient need capnography in the PACU?
 - * What is most appropriate unit for this patient post-op?



Final Thoughts

- ◆ Nurses are a vital part of the perioperative team. You are charged with caring for the patient as she completes emergence from the anesthetic and therefore are an extension of the anesthesiologist throughout the PACU period.
- ◆ Collaboration with the anesthesia provider is mandatory to optimize care of the patient by knowing the airway management used and anticipating possible adverse events.



References

- ◆ Atlas of Airway Management, second edition. Orebaugh, SL. Lippincott Williams & Wilkins, 2012.
- ◆ A Brief History of Clinical Airway Management. Doyle, DJ. *Anesthesiology*; 2009; 32(1):164-167.
- ◆ Miller's Anesthesia, seventh edition. Miller, RD, Editor. Churchill Livingstone, 2010
- ◆ Gregory's Pediatric Anesthesia, fifth edition. GA Gregory and DB Andropoulos, Editors. Wiley-Blackwell, 2012



THANKS!

Toni Felberg, MD
mafelber@texaschildrens.org